

ACUTE INFLAMMATORY DEMYELINATING POLYRADICULONEUROPATHY (AIDP) FOLLOWING PLASMODIUM VIVAX MALARIA – A CASE REPORT

Tony Ete, Sumantro Mondal, Debanjali Sinha, Kaushik Bhar, Soumik Sarkar, Jyotirmoy Pal, Alakendu Ghosh
Institute of Post Graduate Medical Education and Research, Kolkata, West Bengal, India

Correspondence to: Tony Ete (tetepete@gmail.com)

DOI: 10.5455/ijmsph.2014.020220141

Received Date: 23.01.2014

Accepted Date: 02.03.2014

ABSTRACT

Acute Inflammatory Demyelinating Polyradiculoneuropathy (AIDP) is usually preceded by infection with certain bacteria and viruses. Parasitic infection has rarely been reported as a causal factor for AIDP. Neurological manifestations following malaria is commonly seen with *P. falciparum*. There are only few case reports of Guillain-Barré Syndrome or facial diplegia following *P. vivax* infection. Here we are reporting a patient who developed AIDP and facial diplegia within two weeks following successful treatment of *P. vivax* infection.

Key Words: Plasmodium vivax; Acute Inflammatory Demyelinating Polyradiculoneuropathy (AIDP); Facial Diplegia

Introduction

Neurological manifestations following malaria is uncommon with a prevalence of 0.12%. It is 299 times more common in complicated falciparum malaria than uncomplicated type.^[1] Most of the post malarial neurological symptoms (PMNS) are seen with *P. falciparum* infection. PMNS following *P. vivax* infection is much rarer but there is no epidemiological data regarding the actual incidence. AIDP following *P. vivax* infection is very rarely reported. Our patient presented with AIDP and facial diplegia following recent recovery from *P. vivax* infection and after a thorough search no other causative factor could be elicited. In this case the neurological manifestations could be considered to be the consequence of *P. vivax* infection.

Case Report

A 22 year old male, presented with weakness of all four limbs for two weeks. He had a history of high fever with chill and rigor for five days, about two week prior to the development of quadriplegia. There was no history of cough, diarrhea or rash. His fever was diagnosed to be due to vivax malaria by demonstration of trophozoites of *P. vivax* in peripheral blood smear (Figure 1) and positive *P. vivax* antigen test. He received three doses of oral chloroquine (600 mg stat, 600 mg after 24 hours and 300 mg after 48 hours of first dose) and advised for oral primaquine (15 mg x 14 days). After an afebrile period of ten days, he developed progressive weakness of lower limbs involving both the proximal and distal muscles. Weakness gradually ascended rostrally to involve his upper limbs within a time span of one week. He also had subjective sensory symptoms and aching pain in lower limbs. During second week of his illness he developed

difficulty in deglutition, dribbling of saliva from both angle of mouth and inability to close both eyelids and eventually facial diplegia. At the end of second week the patient was completely bed ridden. There was no history of any root pain, girdle like sensation, anaesthesia, and hyperesthesia or bladder/bowel involvement. Examination revealed, bilateral lower motor neuron type of Facial nerve palsy and hypoactive gag reflex. Limbs were hypotonic. Power was diminished in all four limbs (lower limb-1/5 and upper limb-2/5) associated with generalised areflexia. Plantar reflex was non responsive bilaterally. Exteroceptive and proprioceptive sensory modalities were unaffected. Complete hemogram, liver, renal, thyroid Function tests, blood glucose and electrolytes were within normal limit. HIV serology was negative. Peripheral blood smear did not show any malaria parasite. *P. falciparum* antigen was negative. CSF study showed albuminocytological dissociation (cell count: 5/cmm all mononuclear cells and protein: 282 mg/dl). CSF glucose-60 mg/dl. CSF gram stain, AFB stain, fungal and mycobacterial culture were negative as well as negative HSV PCR study. Chest X-ray and MRI brain and spinal cord were normal. Nerve conduction study showed decreased CMAP amplitude in both upper and lower limbs with conduction block in left median, left ulnar and right peroneal nerve with significantly decreased conduction velocity (<70%) and markedly increase distal latency (>130%) with absent SNAP in upper limb with preserved sural SNAP with absent 'H' and 'F' reflex in both upper and lower limbs consistent with a diagnosis of AIDP. The patient was treated with plasmapheresis. Signs of improvement noted at the end of first week. Tone and power of limbs improved over next two weeks and he was able to take food orally during this period. He was discharged in stable condition after three weeks from his admission.

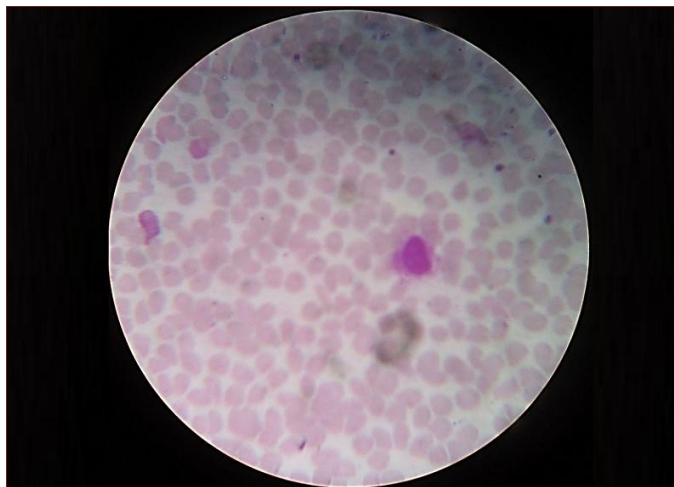


Figure-1: Peripheral blood smear showing trophozoites of *P. vivax*

Discussion

In this patient the diagnosis of AIDP was evident from clinical features and later on confirmed by the typical CSF changes and nerve conduction studies. AIDP usually occurs following upper respiratory tract infections and gastrointestinal infections. The most frequently identified organisms are *Campylobacter jejuni* and cytomegalovirus.^[2] Other infections known to trigger AIDP are HIV, Epstein-Barr virus, Hemophilus, Influenza, Coxsackie and herpes simplex. Surprisingly in our patient the development of AIDP was heralded by infection with *P. vivax*. The patient developed AIDP after an interval of ten days afebrile period. After extensive search for common etiological agents of AIDP, we failed to find any; neither the patient had any prior history of respiratory, gastrointestinal infection or vaccination. *P. vivax* malaria was considered as benign in the past but the scenario has changed. There is increasing incidence of serious complications being reported in association with *P. vivax* malaria. Neurological complications after *P. falciparum* is not uncommon and it encompasses cerebral malaria, myelitis and post malarial neurological syndrome characterized by an acute confusional state, acute psychosis, inappropriate speech, visual hallucination, convulsion, tremor, and hypotonia.^[4] PMNS occurs after the clearance of parasitemia and is not a manifestation of cerebral malaria. On the contrary, neurological involvement is very rare in *P. vivax* malaria and it ranges from ADEM, cerebral malaria and myelitis during parasitemia and PMNS.^[3,4] *P. vivax* malaria as a cause of AIDP is extremely uncommon and only few cases have been reported before.^[5-7] Though unclear, the possible pathogenic mechanisms responsible for neuronal insult in malaria is immune mediated myelin and axonal damage. Immune mediated peripheral nerve damage may also see in a previously infected person due to memory immune response.^[8] Parasitic emboli obstructing

vasa nervosum, release of neurotoxins, metabolic, immune-mediated capillary damage, release of free radicals and cytokines are also hypothesized for the development of polyneuropathy.^[9] Temporary demyelination of peripheral nerves can occur following vascular occlusion by parasites.

As per few literatures, long term use of chloroquine in arthritis patients may cause areflexic weakness.^[10,11] But there are no evidence of similar incident with short term use of chloroquine in malaria. Again normal electrolytes level and thyroid profile virtually exclude any possibility of channelopathy in this patient. Acute transverse myelopathy could also be reasonably excluded by a normal MRI of spine. Facial diplegia has previously been reported following *P. vivax* infection.^[11] In our patient facial diplegia can be considered as a spectrum of AIDP.

Conclusion

This case report is concerned with the development of AIDP and facial diplegia following *P. vivax* infection. To the best of our knowledge this combination of PMNS following *P. vivax* malaria has not as been reported before.

References

1. Nguyen TH, Day NP, Ly VC, Waller D, Mai NT, Bethell DB, et al. Post-malaria neurological syndrome. *Lancet*. 1996;348(9032):917-21
2. Zhong M, Cai FC. Current perspectives on Guillain-Barré syndrome. *World J Pediatr*. 2007; 3 (3): 187-194.
3. Kochar DK, Saxena V, Singh N, Kochar SK, Kumar SV, Das A. *Plasmodium vivax* malaria. *Emerg Infect Dis*. 2005; 11(1):132-34.
4. Moulick A, Maitra S, Sarkar BS, Jana A, Sarkar S. *Vivax* malaria presenting with myelitis: a rare complication. *J Clin Diagn Res*. 2013;7(5):914.
5. Padmini R, Maheshwari MC. *P. vivax* malaria complicated by peripheral neuropathy with electrophysiological studies. *J Assoc Physicians India*. 1980;28:152-6
6. Chakravarty A, Ghosh B, Bhattacharyya R, Sengupta S, Mukherjee S. Acute inflammatory demyelinating polyneuropathy following *Plasmodium vivax* malaria. *Neurol India*. 2004;52(1):130-1.
7. Kanjalkar M, Karnad DR, Narayana RV, Shah PU. Guillain-Barre syndrome following malaria. *J Infect*. 1999;38:48-50.
8. Wijesundere A, Guillain Barre Syndrome in *Plasmodium falciparum* malaria. *Postgrad Med J* 1992;68 (799):367-377.
9. Conner DH, Herber JM. Parasitic infections of the peripheral nervous system. In: Dyck PJ, Thomas PK, eds. *Peripheral Neuropathy*. Philadelphia: WB Saunders; 1993. 1338-90
10. Becerra-Cuñat JL, Coll-Cantí J, Gelpí-Mantius E, Ferrer-Avellí X, Lozano-Sánchez M, Millán-Torné M, et al. Chloroquine-induced myopathy and neuropathy: progressive tetraparesis with areflexia that simulates a polyradiculoneuropathy. Two case reports. *Rev Neurol*. 2003; 36(6):523-6. [Article in Spanish]
11. Sim JE, Choi YC, Kim WJ. Facial Diplegia in *Plasmodium vivax* Malaria. *J Clin Neurol*. 2010;6:102-3.

Cite this article as: Ete T, Mondal S, Sinha D, Bhar K, Sarkar S, Pal J, et al. Acute Inflammatory Demyelinating Polyradiculoneuropathy (AIDP) following *Plasmodium vivax* malaria – A case report. *Int J Med Sci Public Health* 2014;3:517-518.

Source of Support: Nil

Conflict of interest: None declared